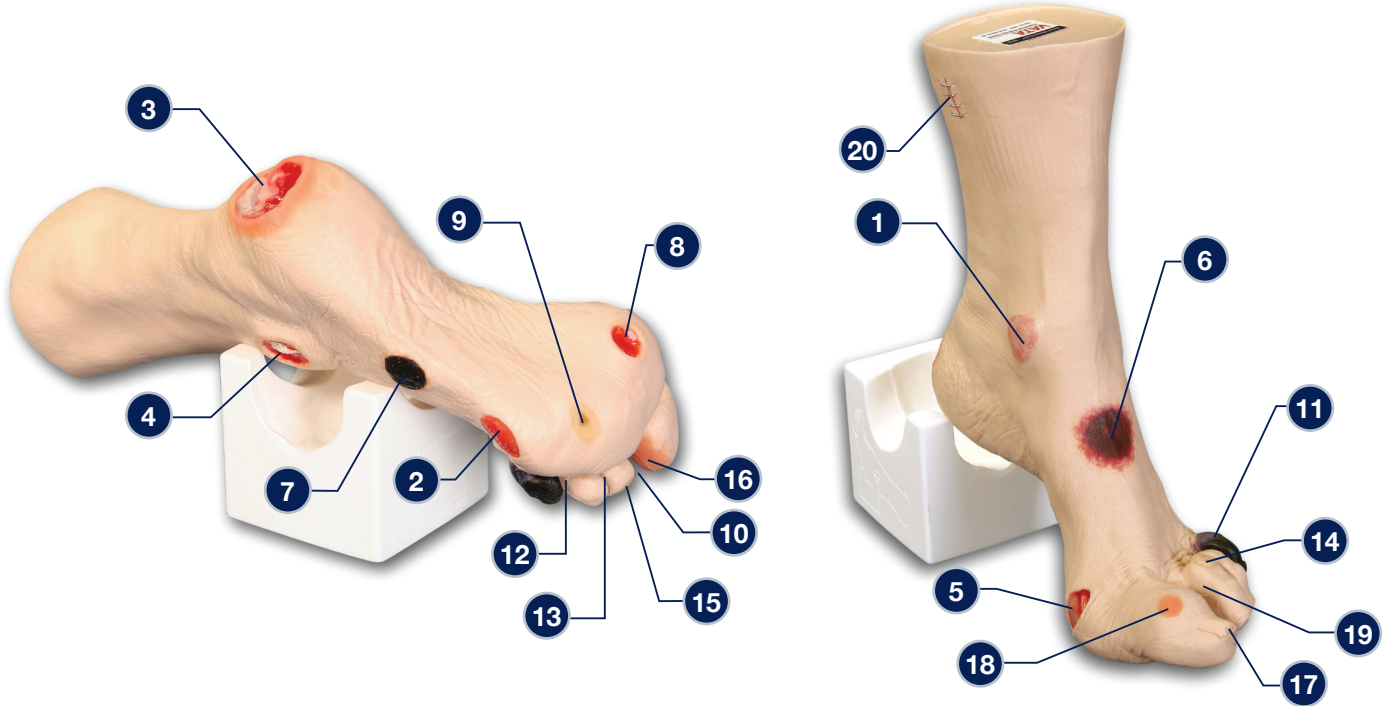


## Wilma Wound Foot™ – 0950



### The following wounds\*, pressure injuries\* and foot abnormalities are presented on Wilma Wound Foot™

- 1 Stage 1 pressure injury on the medial malleolus
- 2 Stage 2 pressure injury on the lateral foot (behind the 5th toe)
- 3 Stage 3 pressure injury on the heel with infection
- 4 Stage 4 pressure injury on the lateral malleolus with exposed tendon and bone (with osteomyelitis)
- 5 Stage 4 pressure injury on the medial foot (behind the great toe) with exposed tendon and slough
- 6 DTPI (Deep Tissue Pressure Injury) on top of foot with “mushy/boggy” feel when palpated
- 7 Eschar (unstageable) on lateral foot
- 8 Full thickness ulcer, plantar, 1st digit, probable diabetic neuropathic etiology
- 9 Callus under the 4th metatarsal phalangeal joint
- 10 Amputated 2nd toe
- 11 Dry gangrene of the 5th toe, due to ischemia
- 12 Interdigital maceration between the 4th and 5th toe
- 13 Partial thickness wounds between 3rd and 4th toe at 1st joint
- 14 Corn at base of 3rd toe
- 15 Callus at tip of 3rd toe
- 16 Ingrown toenail on the medial aspect of the great toe
- 17 Fungal thickened toenail on the great toe
- 18 Blister on great toe at the first joint
- 19 Hammer toes - 3rd, 4th and 5th toes
- 20 Skin stapled wound

\* We have included the most likely etiology-based descriptions, but realize many wounds can appear in the same location, having different etiologies. The definitive diagnosis is up to the clinician and interprofessional wound care team.

**Care Instructions:** To clean your model VATA recommends soap and warm water. Some customers have found applying a barrier/skin prep can give them the adhesion they are looking for.

